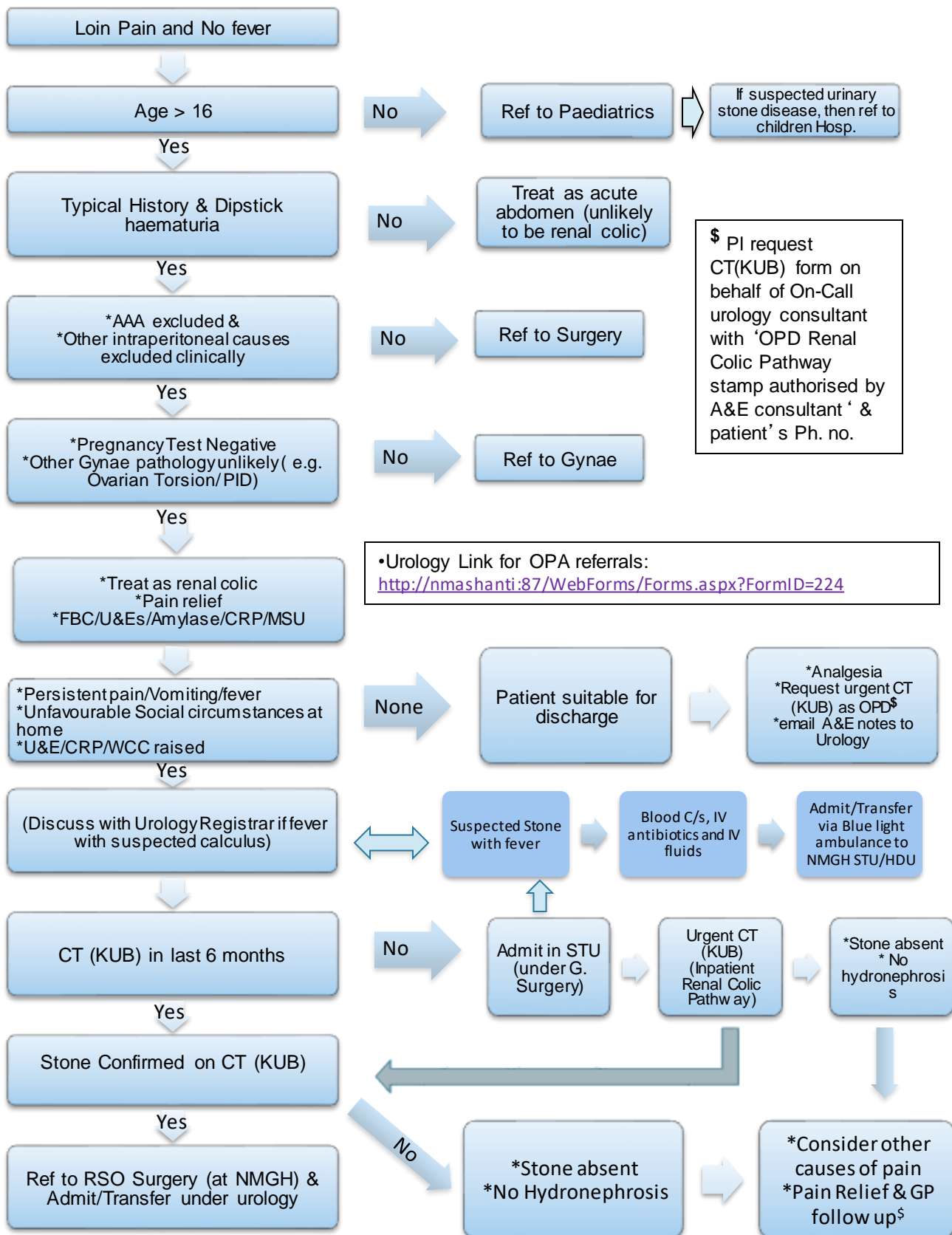


Pennine Acute Trust Renal Colic Pathway



\$ In patients with negative CT (KUB) report within 6 months, but high clinical suspicion of renal colic/ known metabolic stone disease/ confirmed recurrent stone disease; consider review of CT images by uro-radiologist +/- repeat CT (KUB)/CT Urogram to conclusively exclude renal colic